



Knee extension among patients with damaged anterior cruciate ligament

Ocena wyprostów stawu kolanowego u pacjentów z uszkodzonym więzadłem krzyżowym przednim

Jakub Sojat^{1,2,B,D}, Michał Szlęzak^{1,2,A-B}, Dagmara Wasiuk-Zowada^{3,C-D}, Karolina Paździora^{4,E},
Wirginia Likus^{1,E-F}

¹ Department of Anatomy, Faculty of Health Sciences in Katowice, Medical University of Silesia, Katowice, Poland

² Association of Neurophysiological-Orthopaedic Manipulative Physical Therapists, Katowice, Poland

³ Department of Physiotherapy, Faculty of Health Sciences in Katowice, Medical University of Silesia, Katowice, Poland

⁴ Student's Scientific Association at The Department of Anatomy, Faculty of Health Sciences in Katowice, Medical University of Silesia, Katowice, Poland

A – Research concept and design, B – Collection and/or assembly of data, C – Data analysis and interpretation, D – Writing the article, E – Critical revision of the article, F – Final approval of article

Sojat J, Szlęzak M, Wasiuk-Zowada D, Paździora K, Likus W. Knee extension among patients with damaged anterior cruciate ligament. Med Og Nauk Zdr. doi: 10.26444/monz/174215

Abstract

Introduction and Objective. A common belief is that after an anterior cruciate ligament (ACL) injury, there is a deficit knee range of motion (ROM). Deficit ROM can be caused by swelling, postoperative or postinjury pain. However, in the literature there is a lack of papers proving that there is a deficit of knee joint extension ROM after ACL injury. The aim of the study was to compare the knee joint extension range between the healthy limb and the limb with an anterior cruciate ligament (ACL) injury.

Materials and Method. The study was performed on a group of 44 patients aged 18–46 years with ACL injury (non-operative). The diagnosis was made on the basis of functional tests: Lachman test, pivot shift test, anterior drawer test, confirmed by MRI examination. ACL damage was also diagnosed in the MRI report by a radiologist. A Saunders inclinometer was used to measure passive and active knee extension.

Results. There was a significant difference in the measurements of knee extension between a healthy limb and a limb with an ACL injury (active extension $p=0.0012$; passive extension $p=0.0122$).

Conclusions. The limb with ACL injury had a lower range of extension in comparison to the healthy limb. Therefore, treatment focusing on improving the range of extension seems to be beneficial in patients' recovery. It is important to examine both the active and passive knee extension range of motion after ACL damaged.

Key words

knee injuries, knee extension, Anterior Cruciate Ligament, non-operative treatment

Streszczenie

Wprowadzenie i cel pracy. Powszechnie uważa się, że po urazie więzadła krzyżowego przedniego (ACL) występuje ograniczenie ruchomości stawu kolanowego. Jest wiele przyczyn ograniczenia ruchu, m.in. opuchlizna, ból pourazowy, jednakże w literaturze brakuje prac przedstawiających zjawisko, którym jest deficyt wyprostów stawu kolanowego po urazie ACL. Celem pracy było porównanie zakresu ruchu wyprostów stawu kolanowego między kończynami dolnymi u pacjentów po uszkodzeniu więzadła krzyżowego przedniego.

Materiał i metody. Badanie zostało przeprowadzone w grupie 44 pacjentów z uszkodzonym ACL (nieoperowanym). Diagnostyka została oparta na wynikach testów funkcjonalnych: testu Lachmanna; testu pivot shift oraz testu szuflady przedniej. Ponadto w obrazie rezonansu magnetycznego musiało być potwierdzone uszkodzenie ACL. Dodatkowo uszkodzenie ACL musiało być potwierdzone w opisie przygotowywanym przez lekarza specjalistę radiologii. Zakres wyprostów mierzono zarówno pasywnie, jak i aktywnie za pomocą inklinometru Saundersa.

Wyniki. Kończyna z uszkodzonym ACL ma mniejszy zakres wyprostów w porównaniu do kończyny zdrowej. (Aktywny zakres wyprostów $p = 0,0012$; bierny zakres wyprostów $p = 0,0122$).

Wnioski. Leczenie zorientowane na poprawę zakresu ruchomości wydaje się odpowiednie w powrocie do pełnej sprawności funkcjonalnej pacjentów z uszkodzeniem ACL. U pacjentów po uszkodzeniu ACL zawsze należy badać zakres wyprostów zarówno w formie czynnej, jak i biernej.

Słowa kluczowe

więzadło krzyżowe przednie, uraz kolana, wyprost kolana, leczenie nieoperacyjne

INTRODUCTION

The function of the knee joint after Anterior Cruciate Ligament (ACL) reconstruction has been extensively described in the literature. Authors have mainly focused on the postoperative range of motion, knee proprioception,

Address for correspondence: Jakub Sojat, Department of Anatomy, Faculty of Health Sciences in Katowice, Medical University of Silesia, Katowice, Poland; Association of Neurophysiological-Orthopaedic Manipulative Physical Therapists, Medyków 18, 40-752 Katowice, Poland
E-mail: jakub.sojat.med@gmail.com

Received: 18.08.2023; accepted: 16.10.2023; first published: 27.10.2023

and other important factors influencing knee function [1–11]. However, there is a paucity of research describing the function and, in particular, the range of motion of the knee joint after ACL injury without reconstruction.

The ACL stabilizes the knee joint by attaching proximally to the inner surface of the lateral femoral condyle, and distally to the anterior intercondylar region of the tibia [12]. The ACL wraps around the posterior cruciate ligament (PCL), and together with the PCL firmly connects the femur to the tibia. Together with the collateral ligaments, the ACL guides the articular condyles during joint movement [13].

The X-shaped arrangement of the anterior and posterior cruciate ligaments results in their strong tension in almost all positions of the joint, which explains their important role in stabilizing the knee joint, especially in flexion [14]. If both ACLs sustain damage, the femur and tibia may slide back and forth in relation to each other, causing symptoms of instability [15] (positive drawer test). It is also worth considering the pathomechanics of the knee joint after ACL injury. The ACL prevents strenuous valgus and varus positions of the knee during extension, flexion, and internal rotation. Damage to the ACL results in impaired control of flexion and extension movements. [16]. During extension, the anterior ACL and posterior PCL ligaments are tightened. After ACL injury, there is a decrease in the range of motion of the knee joint. Surprisingly, the unstable joint shows a reduced range of motion [17]. It should be noted that the ACL is highly mechanosensitive innervated, suggesting that it plays an important mechanosensory role [18]. Therefore, ACL damage is also associated with disorders of the proprioceptive system, which impairs the neuromuscular mechanism of knee joint control. In addition, ACL damage is associated with pain, a sensation of instability, and oedema [19, 20]. These and other factors can lead to significant differences in the range of motion between the limbs.

Under physiological conditions, the measurement results should be close to each other, and large differences between the results may indicate pathological changes. Several publications describe the deficits in an extension of the knee joint after ACL injury and reconstruction [6, 7, 11, 17]. However, few describe the condition of patients after ACL injury without reconstruction.

The aim of this study was to investigate whether there are statistically significant differences in the parameters of knee joint extension, measured in both passive and active tests, between the healthy limb and the limb with an ACL injury

MATERIALS AND METHOD

The study was conducted in a group of 44 men aged 18–46 years (Tab.1), mean age – 24.93 years (\pm 6.83 years), with isolated ACL damage. The patients were examined 5–52 weeks after injury (mean 20 weeks, SD 15). Most patients (n=19) were examined within 11–19 weeks of ACL injury. (Fig. 1)

The first inclusion criterion for the study was a diagnosis of ACL damage based on physical examination, MRI imaging, and subjective patient-reported instability of the joint. Physical examination included a standard knee examination with the Lachman test [21], anterior drawer test [22], and pivot shift test [23], performed by a physician. MRI

Table 1. Characteristic of study group (n = 44)

Features	Mean	SD	Min.	Max.
Age [years]	24.93	6.83	18.00	46.00
Height [cm]	177.80	5.61	164.00	188.00
Body weight [kg]	78.68	9.93	58.00	98.00
BMI	24.85	20.31	29.75	2.59

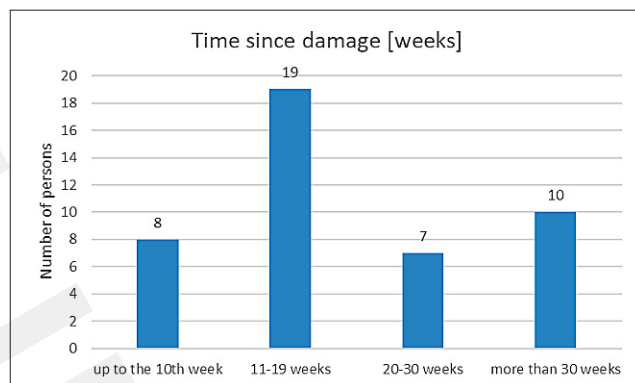


Figure 1. Time interval between the injury and the physical examination

imaging was performed in T1- and T2-weighted sequences in the sagittal, transverse, and axial planes, as well as in the plane along the course of the ACL. ACL injury was based on the radiologist's description. Other inclusion criteria were: a painless knee flexion range of at least 90 degrees and the ability to move independently without the use of orthopedic crutches. Exclusion criteria included: pain on examination, ACL damage in both knee joints, extension deficit greater than 30 degrees, advanced degenerative changes of the knee in stages III and IV visible on MRI, and previous orthopaedic surgery on the lower limbs. All examinations were performed at an Orthopaedics Medical Centre

Due to the retrospective nature of the research, it did not require the approval of a Bioethics Committee. Data confidentiality was respected in accordance with the Helsinki Declaration.

Examination of knee joint extension range using Saunders inclinometer. The study was carried out by 2 researcher physiotherapists, one of whom took the measurements with an inclinometer, while the other was responsible for stabilizing the patient and assisting with movement during the passive examination. The patient lay supine on a medical couch with his lower legs lowered from the couch and his popliteal fossa placed on the edge of the couch. The patient reported no symptoms of neural or vascular pressure in this area. The examiner stabilized the limb being examined by placing one hand on the thigh, 3 cm proximal to the base of the patella. His other hand stabilized the distal part of the tibia from the dorsal side. In the passive test (Fig. 2), the examiner extended the patient's knee joint, without the patient's active involvement, until hard joint or muscle resistance was felt, or until the patient reported discomfort. In the active test (Fig. 3), the patient performed extension of his knee until the same borderline sensations as described above were achieved. The first examiner stabilized the final position of the joint and the second examiner read the measurement result. The inclinometer was always applied to the tibia below the tibial tuberosity at its anterior edge.

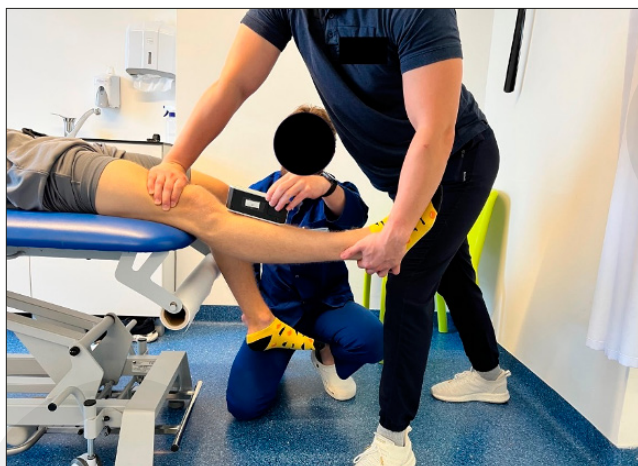

Figure 2. Examination of the passive extension in knee joint

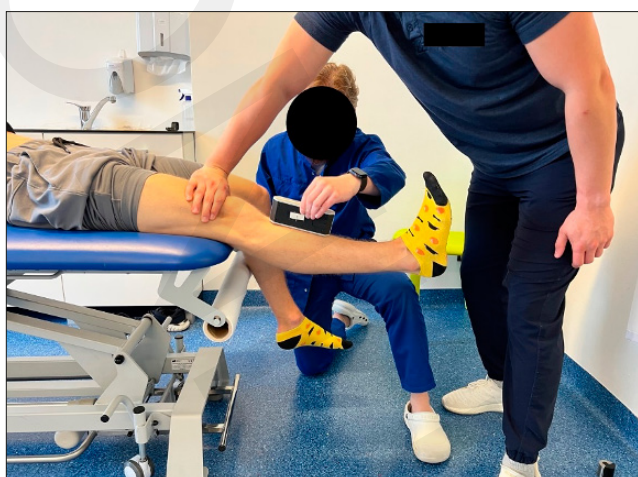

Figure 3. Examination of the active extension in the knee

The inclinometer was calibrated and horizontally zeroed before measurement.

The result of the measurement represents the position of the tibia in relation to the horizontal plane in line with the stabilized femur. Measurements were taken twice and the average of the two measurements was calculated. The Shapiro-Wilk test was used to calculate the normality distribution. Differences between measurements were calculated using Student's t-test for independent samples ($\alpha < 0.05$). Calculations were made in TIBCO Statistica 13.3.

RESULTS

Statistical analysis revealed significant differences in knee joint extension parameters between the healthy and ACL-injured limbs for both passive ($p = 0.0012$) and active ($p = 0.0122$) test measurements (Figs. 4–5). The minimum, maximum, and standard deviation of the knee extension measurements are shown in Table 2.

DISCUSSION

There are few publications in the literature that describe the limitations of knee range of motion in patients with ACL injury. Muneta et al. investigated the correlation between

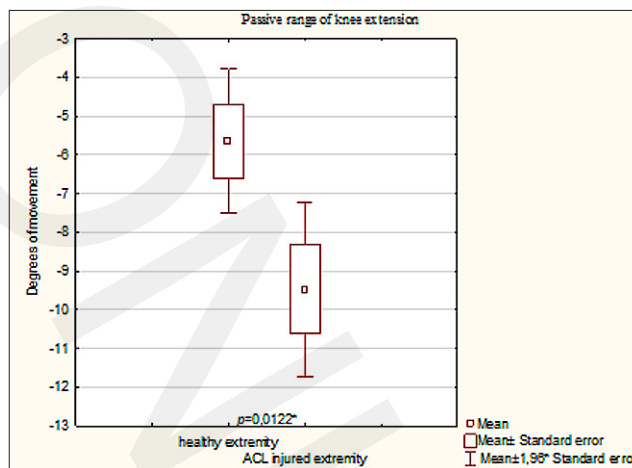


Figure 4. Comparison of passive extension movement between a healthy knee and with damaged ACL

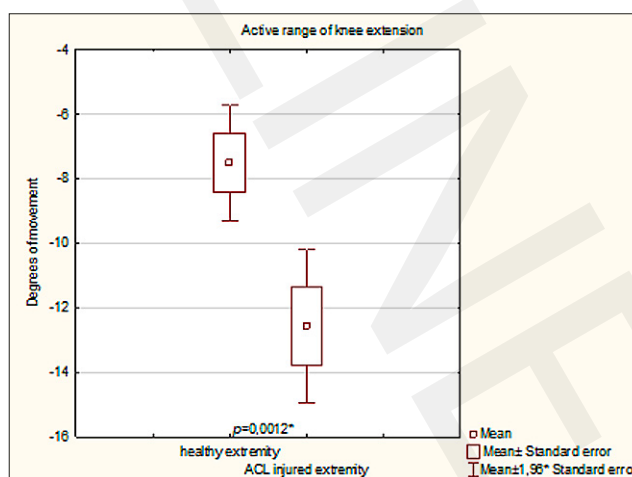


Figure 5. Comparison of active extension movement between a healthy knee and with damaged ACL

Table 2. Active and passive movement test results of extension range in healthy and ACL injured knee [°]

Variant	Mean	SD	Min.	Max.	p
Active range of knee extension – healthy extremity	-7.51	6.07	-16.50	10.00	0.0012*
Active range of knee extension – ACL injured extremity	-12.59	8.05	-36.00	8.00	
Passive range of knee extension – healthy extremity	-5.65	6.30	-21.50	10.50	0.0122*
Passive range of knee extension – ACL injured extremity	-9.47	7.63	-28.50	7.00	

* < 0.05

knee extension deficit after ACL injury and time elapsed since the injury in a study group of 81 patients with ACL injury. The patients were treated both surgically (ACL reconstruction) and non-surgically (conservative treatment), and were divided into 2 groups: Group 1 with an acute condition (17 patients, 3 weeks after the injury) and Group 2 with a chronic condition (64 patients, more than 3 weeks after injury) [24]. Both the healthy limb and the limb with the injured ACL were examined, and the range of extension was measured on plain radiographs. It was found that in both groups the range of knee extension in the limb with the ACL injury was

smaller than in the healthy limb. Also found was that the knee extension deficit after ACL injury correlated positively with the time since ACL injury.

Additionally, a subgroup of 12 patients (mean age 33 years) with ACL injuries who did not require ACL reconstruction could be distinguished from the acute group (Group 1). In this group of patients, the range of motion of the knee joint was assessed twice: the first time 3 weeks after the ACL injury and the second time, on average, 208 days after the injury [24]. The authors found an increase in knee extension range at the second measurement. It is important to note that Muneta et al. only assessed the range of extension using a passive test and did not assess the active movements, which play an important role in assessing and improving the patient's functionality. Based on their studies, Szlęzak et al. found that the passive flexion range of the limb with an ACL injury was positively correlated with the extension range of active movement of the injured joint. Therefore, it can be assumed that the absence of the ACL determines the reduced range of extension and flexion of the knee joint [17].

Berend et al. also demonstrated a relationship between the absence of the ACL and the reduction in the range of motion of the joint described. The authors studied a group of patients undergoing total knee arthroplasty (TKA) and assessed differences in the preoperative range of motion. The study group consisted of 1,656 knees of patients undergoing TKA [18]. The authors found that the mean range of extension was lower in patients with a damaged ACL who were eligible for TKA than in the group of patients with a preserved ACL [18]. In a study by Schreiber et al. comparing 2 types of reconstruction in a group of 99 patients [4], measurements of knee joint extension showed that the mean values of their results were lower in the operated limb, compared to the unoperated limb.

The above observations referred to measurements taken at both one and 3 months after ACL reconstruction and occurred in patients who underwent either one or the other method of reconstruction.

Other authors have indicated the overloading of the patellofemoral joint that occurs in patients after ACL reconstruction with an extension deficit [25]. To better understand these problems, Sachs et al. investigated the relationship between extension deficit and patellar irritability (including crepitations). They measured the degree of deficit by performing active extension of both knee joints, with the patient supine. The authors confirmed that a greater extension deficit showed a positive correlation with patellar irritability [26]. Sachs et al. showed that the extension deficit leads to an increase in the compressive contact forces in the patellofemoral joint and, as a result, may lead to pain symptoms in the anterior part of the joint [26]. This mechanism was explained by Hong, who noted that in patellofemoral joint dysfunction, the patella has difficulty maintaining the correct path of motion concerning the trochlear groove [27].

Physiologically, the patella moves up and down along with flexion and extension of the knee [28]. In the presence of pathological changes, the movement of the patella may be disturbed. In addition, Hong stated that the above phenomenon may be accompanied by pain in the anterior part of the knee [27]. Consequently, patients with knee extension deficits who experience pain in the anterior part of the joint may show dysfunction of the patellofemoral joint. Apart from

the knee extension deficit, after ACL damage, it is important to consider the potential symptomatic manifestation in the form of muscle stiffness. Kuszewski et al. examined the passive stiffness of hamstring muscles and rectus femoris muscle in a group of patients after ACL reconstruction, and compared their results with those obtained in the control group of patients with healthy limbs [5]. The authors proved that in the study group, the stiffness of the examined muscles was greater than in the control group.

It is worth mentioning that often in the medical world, authors aim to identify or propose the most effective and successful treatment after ACL injury. Literature reports usually focus on the comparison between therapeutic outcomes of conservative treatment (usually an improvement process) vs. surgical treatment (early ACL reconstruction) [29,30]. The authors emphasize that at a longer follow-up of patients of 24 months (Reijman [29]) and 18 months (Beard [30]), statistically better results were achieved when ACL reconstruction is implemented early after the injury.

The authors of these studies specifically note the reduction in symptoms related to pain, instability, and improved quality of life among patients undergoing early surgical intervention [30]. On the other hand, Beard et al. studied patients based on the Knee Injury and Osteoarthritis Outcome Score-4, and showed that the scores of this questionnaire increased in patients undergoing ACL reconstruction compared to those undergoing rehabilitation [30].

The above studies may be an interesting reference in relation to the current management of patients after ACL injury. It is worth noting that early surgical intervention will predispose to an improvement in the quality of life, but it should also be remembered that not reconstruction alone, but coupled with other physiotherapeutic treatment, will be the main factor in reducing symptoms and improving the quality of life after ACL reconstruction.

While analysing the data obtained for the presented study, it is important to remember that the predisposing factor for knee joint extension deficits is an ACL injury. Upright deficits should be addressed in both reconstructed and conservatively treated patients. In addition, Celik et al. conducted a study on the use of a form of Pilates as a form of training/treatment in patients who had not undergone ACL reconstruction [31]. The authors demonstrated that after 12 weeks of this type of training, quadriceps strength, sense of stability of the knee joint, and isokinetic test results were statistically significantly increased [31]. It is important to add that various forms of physiotherapy will have a positive effect on the functional status of the knee joint after an ACL injury. Furthermore, it is important to remember that to achieve a good functional state of the knee joint, all dysfunctions of the knee joint should be treated, especially the knee extension deficit shown to occur after ACL injury in the current study.

Increased stiffness of the hamstring muscles could potentially affect the oblique popliteal ligament (OPL) as one of the arms of the semi-membranous muscle (which is one of the hamstring muscles) is fused with OPL [32–35]. This connection can make OPL an important factor in determining biomechanical disorders and shrinkage of the soft tissues surrounding the popliteal fossa and, in turn, may cause a deficit in knee extension.

A significant problem seems to be the differences in the methodology of the research presented by different authors. The range of extension was tested by plane radiographs

made in the supine position of the patient, an inclinometer used in the supine position [17], a goniometer used in the sitting position [18], and a goniometer used in the prone position of the patient [4]. Each of these differences may play an important role because the parameters tested may be inconsistent, resulting in incomparable results leading to different conclusions. It seems necessary in this case to introduce uniform standards for testing the deficit in the extension of the knee joint, which will allow for a more detailed examination of the described problem, and contribute to the most effective rehabilitation of patients with extension deficits after ACL damage.

The presented study proves that there is a statistically significant difference in knee extension ROM between the healthy lower limb and the lower limb with ACL damage. It is necessary to implement a rehabilitation program to reduce the deficit of knee extension. Reduction of the deficit of knee extension may not lead to dysfunction of the patellofemoral joint and any pain in the knee joint.

Limitations of the study. The study was conducted in a group of 44 men with isolated ACL damage. In the future, it would be worthwhile separating the groups into patients undergoing physiotherapy after ACL injury, and those treated without physiotherapy, to investigate the potential differences in knee joint extension deficit between the groups. In addition, it would be useful to separate the groups according to the daily work performed, showing whether the type of daily activities may have a significant effect on the knee joint extension deficit. In the future it would be worth separating the groups into patients undergoing physiotherapy after ACL injury and those treated without physiotherapy, and examining the issue of knee joint extension deficit in the groups. It would also be worthwhile examining the groups performing different types of daily activities and assess potential differences depending on the type of daily work performed, in order to analyze whether the type of work performed would have a significant impact on the knee extension deficit. The inclusion of female ACL-patients in the future extension of the studies would potentially allow for the assessment of the influence of increased elastin content in female connective tissues, on the initial injury manifestation, and the efficacy of different therapeutic approaches.

CONCLUSIONS

Based on the presented results and the results obtained by other researchers, it seems that the treatment of patients after ACL injury should focus on the normalization of the range of motion in the knee joint. First of all, restoration of the patient's comfort of functioning and to minimize the risk of dysfunction in the patellofemoral joint. It is important to conduct both the active and passive tests of the knee joint extension in patients with ACL injuries, due to their functional differences, which may influence the everyday life of the patient. The analyzed issue suggests the need for further study on soft tissue injuries, and the functioning of the knee joint without ACL reconstruction [36].

REFERENCES

- Magnussen R, Reinke EK, Huston LJ, et al. Anterior and Rotational Knee Laxity Does Not Affect Patient-Reported Knee Function 2 Years After Anterior Cruciate Ligament Reconstruction. *Am J Sports Med.* 2019;47(9):2077–2085. doi:10.1177/0363546519857076
- Laboute E, Verhaeghe E, Ucay O, Minden A. Evaluation kinaesthetic proprioceptive deficit after knee anterior cruciate ligament (ACL) reconstruction in athletes. *J Exp Orthop.* 2019;6(1):6. doi:10.1186/s40634-019-0174-8
- Sugimoto D, Heyworth BE, Yates BA, Kramer DE, Kocher MS, Micheli LJ. Effect of Graft Type on Thigh Circumference, Knee Range of Motion, and Lower-Extremity Strength in Pediatric and Adolescent Males Following Anterior Cruciate Ligament Reconstruction. *J Sport Rehabil.* 2019;29(5):555–562. doi:10.1123/jsr.2018-0272
- Schreiber VM, Jordan SS, Bonci GA, Irrgang JJ, Fu FH. The evolution of primary double-bundle ACL reconstruction and recovery of early post-operative range of motion. *Knee Surg Sports Traumatol Arthrosc.* 2017;25(5):1475–1481. doi:10.1007/s00167-016-4347-z
- Kuszewski MT, Gnat R, Szlachta G, Kaczyńska M, Knapik A. Passive stiffness of the hamstrings and the rectus femoris in persons after an ACL reconstruction. *Phys Sportsmed.* 2019;47(1):91–95. doi:10.1080/0913847.2018.1527171
- Filbay SR, Grindem H. Evidence-based recommendations for the management of anterior cruciate ligament (ACL) rupture. *Best Pract Res Clin Rheumatol.* 2019;33(1):33–47. doi:10.1016/j.berh.2019.01.018
- Musah V, Engler ID, Nazzal EM, Dalton JF, Lucidi GA, Hughes JD, Zaffagnini S, Della Villa F, Irrgang JJ, Fu FH, Karlsson J. Current trends in the anterior cruciate ligament part II: evaluation, surgical technique, prevention, and rehabilitation. *Knee Surg Sports Traumatol Arthrosc.* 2022;30(1):34–51. doi:10.1007/s00167-021-06825-z
- Baxter T, Majumdar A, Heyworth BE. Anterior Cruciate Ligament Reconstruction Procedures Using the Iliotibial Band Autograft. *Clin Sports Med.* 2022;41(4):549–567. doi: 10.1016/j.csm.2022.05.001
- Kunze KN, Manzi J, Richardson M, White AE, Coladonato C, DePhillipo NN, LaPrade RF, Chahla J. Combined Anterolateral and Anterior Cruciate Ligament Reconstruction Improves Pivot Shift Compared With Isolated Anterior Cruciate Ligament Reconstruction: A Systematic Review and Meta-analysis of Randomized Controlled Trials. *Arthroscopy.* 2021;37(8):2677–2703. doi:10.1016/j.arthro.2021.03.058
- Glatcke KE, Tummala SV, Chhabra A. Anterior Cruciate Ligament Reconstruction Recovery and Rehabilitation: A Systematic Review. *J Bone Joint Surg Am.* 2022;104(8):739–754. doi:10.2106/JBJS.21.00688
- Kotsifaki R, Korakakis V, King E, Barbosa O, Maree D, Pantouveris M, Bjerregaard A, Luomajoki J, Wilhelmsen J, Whiteley R. Aspetar clinical practice guideline on rehabilitation after anterior cruciate ligament reconstruction. *Br J Sports Med.* 2023;57(9):500–514. doi:10.1136/bjsports-2022-106158
- Hassebrock JD, Gulbrandsen MT, Asprey WL, Makovicka JL, Chhabra A. Knee Ligament Anatomy and Biomechanics. *Sports Med Arthrosc Rev.* 2020;28(3):80–86. doi:10.1097/JSA.0000000000000279
- Heuck A, Woertler K. Posttreatment Imaging of the Knee: Cruciate Ligaments and Menisci. *Semin Musculoskelet Radiol.* 2022;26(3):230–241. doi:10.1055/s-0041-1741516
- Amis AA. Anterolateral knee biomechanics. *Knee Surg Sports Traumatol Arthrosc.* 2017;25(4):1015–1023. doi:10.1007/s00167-017-4494-x
- Boyd J, Holt JK. Knee Ligament Instability Patterns: What Is Clinically Important. *Clin Sports Med.* 2019;38(2):169–182. doi:10.1016/j.csm.2018.12.001
- Kaeding CC, Léger-St-Jean B, Magnussen RA. Epidemiology and Diagnosis of Anterior Cruciate Ligament Injuries. *Clin Sports Med.* 2017;36(1):1–8. doi:10.1016/j.csm.2016.08.001
- Szlęzak M, Kowal W, Kowal T, et al. Assessment of the correlation between the flexion and extension knee range of motion among patients with injured anterior cruciate ligament. *Journal of Manual Medicine.* 2018;21:11–16.
- Berend ME, Meding JB, Malinzak RA, Faris PM, Jackson MD, Davis KE, Ritter MA. ACL Damage and Deficiency is Associated with More Severe Preoperative Deformity, Lower Range of Motion at the Time of TKA. *HSS J.* 2016;12(3):235–239. doi:10.1007/s11420-016-9504-x
- Musah V, Karlsson J. Anterior Cruciate Ligament Tear. *N Engl J Med.* 2019;380(24):2341–2348. doi:10.1056/NEJMc1805931
- Johnson VL, Guermazi A, Roemer FW, Hunter DJ. Association between radiographic anterior cruciate ligament tear and joint symptoms: Data from the osteoarthritis initiative. *Int J Rheum Dis.* 2020;23:576–581. doi.org/10.1111/1756-185X.13806
- Lachman Sobrado MF, Bonadio MB, Ribeiro GF, Giglio PN, Helito CP, Demange MK. Lever sign test for chronic acl injury: a comparison with

- lachman and anterior drawer tests. *Acta Orthop Bras.* 2021;29(3):132–136. doi:10.1590/1413-785220212903238345
22. Zhao GL, Lyu JY, Liu CQ, Wu JG, Xia J, Huang GY. A modified anterior drawer test for anterior cruciate ligament ruptures. *J Orthop Surg Res.* 2021;16(1):260. doi:10.1186/s13018-021-02381-x
23. İpek D, Zehir S, Dündar A. Is Lever Test Superior to Lachman, Pivot Shift, Drawer Tests in Diagnosing Anterior Cruciate Ligament Injuries? *Cureus.* 2022;14(2):e22049. doi:10.7759/cureus.22049
24. Muneta T, Ezura Y, Sekiya I, Yamamoto H. Anterior knee laxity and loss of extension after anterior cruciate ligament injury. *Am J Sports Med.* 1996 Sep-Oct;24(5):603–7. doi:10.1177/036354659602400507
25. Myer GD, Ford KR, Di Stasi SL, Foss KD, Micheli LJ, Hewett TE. High knee abduction moments are common risk factors for patellofemoral pain (PFP) and anterior cruciate ligament (ACL) injury in girls: is PFP itself a predictor for subsequent ACL injury? *Br J Sports Med.* 2015;49(2):118–22. doi:10.1136/bjsports-2013-092536
26. Sachs RA, Daniel DM, Stone ML, Garfein RF. Patellofemoral problems after anterior cruciate ligament reconstruction. *Am J Sports Med.* 1989;17(6):760–5. doi:10.1177/036354658901700606
27. Hong E, Kraft MC. Evaluating anterior knee pain. *Med Clin North Am.* 2014;98(4):697–717, xi. doi:10.1016/j.mcna.2014.03.001
28. Żelawski M, Starzewska M, Gradzik TS. Imaging of the patellofemoral joint. *J Orthop Trauma Surg Rel Res.* 2014;2(36):54–63.
29. Reijman M, Eggerding V, van Es E, van Arkel E, van den Brand I, van Linge J, Zijl J, Waarsing E, Bierma-Zeinstra S, Meuffels D. Early surgical reconstruction versus rehabilitation with elective delayed reconstruction for patients with anterior cruciate ligament rupture: COMPARE randomised controlled trial. *BMJ.* 2021;372:n375. doi:10.1136/bmj.n375
30. Beard DJ, Davies L, Cook JA, Stokes J, Leal J, Fletcher H, Abram S, Chegwin K, Greshon A, Jackson W, Bottomley N, Dodd M, Bourke H, Shirkey BA, Paez A, Lamb SE, Barker K, Phillips M, Brown M, Lythe V, Mirza B, Carr A, Monk P, Morgado Areia C, O’Leary S, Haddad F, Wilson C, Price A; ACL SNNAP Study Group. Rehabilitation versus surgical reconstruction for non-acute anterior cruciate ligament injury (ACL SNNAP): a pragmatic randomised controlled trial. *Lancet.* 2022;400(10352):605–615. doi:10.1016/S0140-6736(22)01424-6
31. Çelik D, Turkel N. The effectiveness of Pilates for partial anterior cruciate ligament injury. *Knee Surg Sports Traumatol Arthrosc.* 2017;25(8):2357–2364. doi:10.1007/s00167-015-3718-1
32. LaPrade RF, Morgan PM, Wentorf FA, Johansen S, Engebretsen L. The anatomy of the posterior aspect of the knee. An anatomic study. *J Bone Joint Surg Am.* 2007;89(4):758–64. doi:10.2106/JBJS.F.00120
33. Fam LPD, Fruheling VM, Pupim B, Ramos CH, de Moura MFA, Namba M, da Silva JLV, da Cunha LAM, de Oliveira Franco APG, Filho ES. Oblique popliteal ligament – an anatomical study. *Rev Bras Ortop.* 2013;48(5):402–405. doi:10.1016/j.rboe.2012.07.010
34. Hedderwick M, Stringer MD, McRedmond L, Meikle GR, Woodley SJ. The oblique popliteal ligament: an anatomic and MRI investigation. *Surg Radiol Anat.* 2017;39(9):1017–1027. doi:10.1007/s00276-017-1838-7
35. Wu XD, Yu JH, Zou T, Wang W, LaPrade RF, Huang W, Sun SQ. Anatomical Characteristics and Biomechanical Properties of the Oblique Popliteal Ligament. *Sci Rep.* 2017;7:42698. doi:10.1038/srep42698
36. Kaplan Y. Identifying individuals with an anterior cruciate ligament-deficient knee as copers and noncopers: a narrative literature review. *J Orthop Sports Phys Ther.* 2011;41(10):758–66. doi:10.2519/jospt.2011.3384